Off-pump coronary artery bypass surgery

Amarja Sachin Nagre, MD, DM, FCA*

*Amarja Sachin Nagre, Assistant Professor, N-6, Cidco, Aurangabad, Maharashtra 431003, (India)

The rationale behind development of off pump coronary artery bypass (OPCAB) surgery is avoidance of CPB related complications in addition to other advantages like it decreases postoperative morbidity, accelerates recovery and leads to early ICU and hospital discharge. Ultrafast tracking and awake OPCAB under high thoracic epidural are significant advances. Anesthetic management of OPCAB patients is targeted to maintain hemodynamic stability and prevent myocardial ischemia during coronary grafting. Meticulous preanesthetic assessment, monitoring, titrated usage of induction agents, balanced anesthetic technique and vigilance during grafting is the essence of anesthetic management during OPCAB.

Despite the use of shunts and advances in stabilizers and other equipment like starfish, it is at times difficult to graft inferior and posterolateral vessels because of right and left ventricular distension and hemodynamic changes.[1] Still OPCAB is at advantageous end as it causes less blood loss and need for transfusion, less myocardial enzyme release up to 24 hours, less early neurocognitive dysfunction and less renal insufficiency.[2]

Octopus Tissue Stabilizer minimizes the motion of small area of the heart where the bypass graft is to be attached while the rest of the heart continues to beat normally. Starfish is the positioner attached at the cardiac apex which locks the longitudinal axis of the heart, thereby allowing access to coronary vessels of the lateral and posterior walls. Intracoronary shunts secure the blood flow through the coronary vessels during the procedure.

Left anterior descending (LAD) grafting (Figure 1) involves 'displacement' of the heart forward and superior to facilitate LAD anastomosis by placing pericardial stay sutures and mops underneath the heart.

Left circumflex artery (LCX) grafting (Figure 2) is the most critical anastomosis as exposure is difficult which demands lifting the heart and placing it in an unphysiologic position called as 'verticalization', achieved by displacing heart to right side. Placing Octopus stabilizer system leads to compression of the right ventricle and distortion of the tricuspid and mitral annuli. Steps to combat hypotension and hypoperfusion are opening of right pleura to accommodate RV, application of Starfish apical suction device, Trendelenburg position, use of vasopressors and inotropes, judicious volume expansion as excess volume administration causes increase in left ventricular end diastolic volume (LVEDV) and hence left ventricular end diastolic pressure (LVEDP) which leads to decrease in coronary perfusion pressure.

Right coronary artery (RCA) grafting (Figures 3 & 4) may result in severe ischemia during clamping of RCA and complete atrioventricular block attributable to interruption of the blood flow in the AV node artery.[3]

REFERENCES

1. Lazar HL. Should off-pump coronary artery bypass grafting be abandoned?. Circulation. 2013 Jul 23;128(4):406-13. [PubMed] [Free full text] doi:10.1161/CIRCULATIONAHA.113.003388
2. Sellke FW, DiMaio JM, Caplan LR, Ferguson TB, Gardner TJ, Hiratzka LF, Isselbacher EM, Lytle BW, Mack MJ, Murkin JM, Robbins RC. Comparing On-Pump and Off-Pump Coronary Artery Bypass Grafting Numerous Studies but Few Conclusions: A Scientific Statement From the American Heart Association Council on Cardiovascular Surgery and Anesthesia in Collaboration With the Interdisciplinary Working Group on Quality of Care and Outcomes Research. Circulation. 2005 May 31;111(21):2858-64. [PubMed] [Free full text]
3. Chassot PG, Van der Linden P, Zaugg M, Mueller XM, Spahn DR. Off-pump coronary artery bypass surgery: physiology and anaesthetic management. Br J Anaesth. 2004 Mar;92(3):400-13. [PubMed] [Free full text] doi:10.1093/bja/aeh064

★★★★★

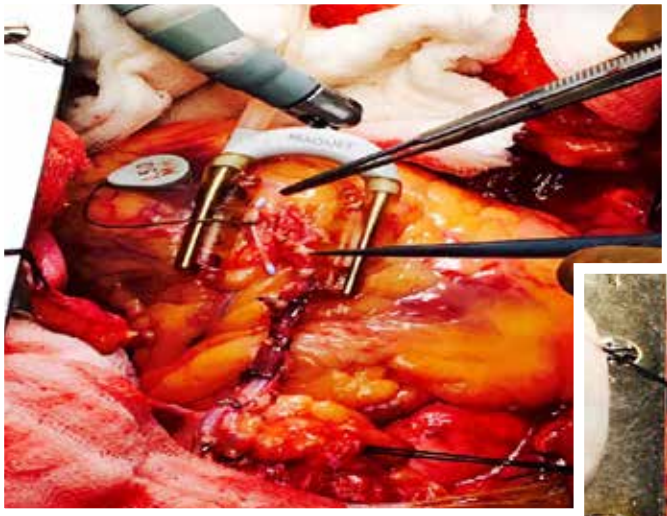

Figure 1: Left anterior descending (LAD) grafting. Intracoronary shunt kept outside the anastomosis for demonstration

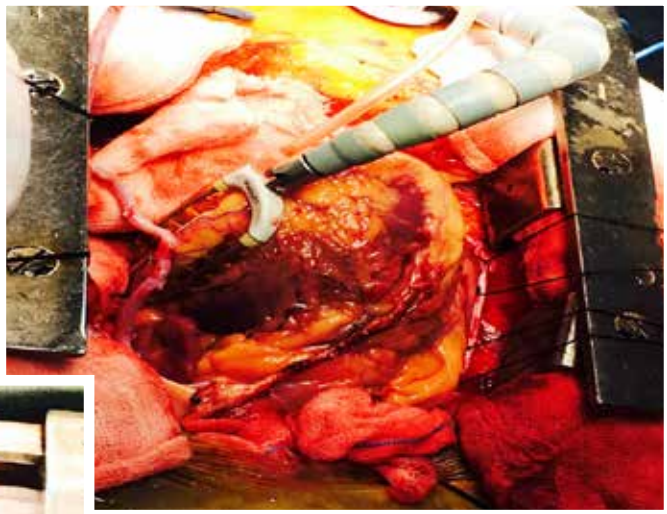

Figure 2: Left circumflex artery (LCX) grafting. Note the 'verticalization' of the heart.

Figure 3: Right coronary artery (RCA) grafting.

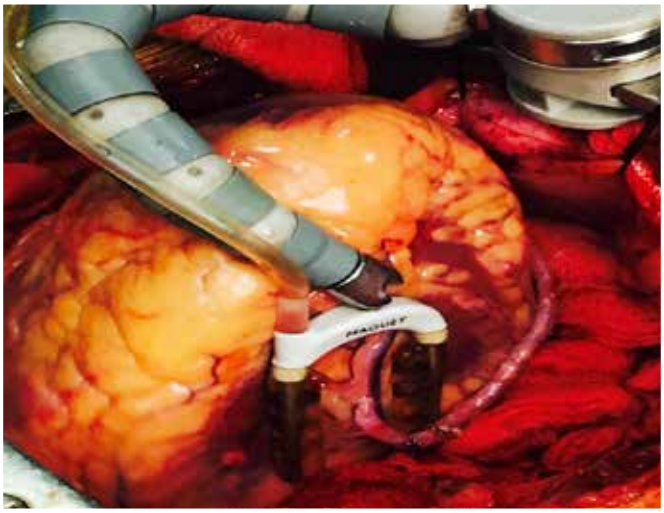

Figure 4: Right coronary artery (RCA) anastomosis.