CASE REPORT

Perioperative management for endoscopic third ventriculostomy: A case report

Safiya I. Shaikh, MD*, Bhagya D.V, MBBS**

*Professor & Head; **Post-graduate student.
Department of Anaesthesiology, Karnataka Institute of Medical Sciences, Hubli , Karnataka (India)

Correspondence: Dr. Safiya I. Shaikh, Professor and Head, Department of Anaesthesiology, Karnataka Institute of Medical Sciences, Hubli–580 022, Karnataka (India); Phone: 0836-2740937; Cell: 09448861706; E-mail: ssafiya1l@yahoo.com

ABSTRACT

Endoscopic third ventriculostomy (ETV) has been accepted as the method of choice in the treatment of obstructive hydrocephalus. The procedure requires general anesthesia and involves manipulation of brain neural structures to access the floor of third ventricle. We report a case discussion of perioperative anesthetic management of a five month old infant with obstructive hydrocephalus for endoscopic third ventriculostomy.

Key words: ETV; Endoscopic third ventriculostomy; Intracranial pressure; ICP.

Citation: Shaikh SI, Bhagya DV. Perioperative management for endoscopic third ventriculostomy: A case report. Anaesth Pain & Intensive Care 2012;16(1):78-81.

INTRODUCTION

ETV has become the standard surgical procedure for treatment of non-communicating hydrocephalus.[1] It is a quick, simple, minimally invasive procedure with less morbidity and mortality compared to standard ventriculo-peritoneal shunt placement.[2,3] A good knowledge of indications, instrumentation, and anesthetic considerations in anticipation of complications arising from this procedure is needed for successful outcome of this technique.[4] Perioperative management of ETV poses a great challenge to the anesthesiologist specially with regard to an associated raised intracranial pressure and the younger age group. We present a case of a young child, who was successfully managed through this procedure at our hospital.

Fig 1: Preoperative picture of the infant.

CASE REPORT

A 5-month old female baby presented with obstructive hydrocephalus, secondary to improperly treated sepsis/ meningitis. She was born preterm and had a birth weight of 1.99 kg. She remained admitted to the hospital in the first month of her life for sepsis and septic shock in NICU for 15 days. Presently, she was brought with the complaints of continuous increase in her head size for four months. On examination, she was alert, conscious and active, her head circumference was 52 cm, had a bulging anterior fontanella and sun set sign was positive. Her heart rate was 126 beats/min and respiratory rate 28 breaths/min. Her Hb was 10.3 gm%. She was scheduled for endoscopic third ventriculostomy. After

a thorough pre-anesthetic examination and preparation, she was accepted for the surgery.

Fig 2: Positioning of the infant for intubation.

Heating mattress and warmed infusions were used to maintain body temperature. In the operating room, her pre-operative heart rate was 125 beats/min and SpO_2 99% at room air. A difficult intubation was anticipated due to large head size, so a meticulous preoperative preparation was done for difficult airway management, including different types of laryngoscope blades and LMA. She was premedicated with inj. glycopyrolate 0.04mg, inj. midazolam 0.1mg and inj. fentanyl 8µg IV. Inj. Dexamethasone 2mg was given. Preoxygenation was done for 5 min and anesthesia was induced with inj. thiopentone 25mg IV. An assistant pushed his hand beneath the upper chest of the baby to raise it slightly and the head was fixed in position by means of small rolled towels on each side. After confirming successful mask ventilation with 100% oxygen, oral intubation was done with inj. succinyl choline 4mg IV. Bilateral air entry was confirmed and the tube secured. Inj. atracurium 2mg bolus was given for muscle relaxation and repeated for maintenance at regular intervals. Anesthesia was maintained intraoperatively with isoflurane in 50% O_2 and N_2O. Positive pressure ventilation was done with an inspiratory pressure set at 12cmH2O and a respiratory rate of 30-35 breaths/min, with a target $EtCO_2$ of 30 mmHg. She remained stable throughout the procedure with heart rate fluctuating between 120-130 beats/min. The course of anesthesia remained uneventful. At the end of the procedure, baby was reversed with inj. neostigmine 0.2mg IV plus inj. atropine 0.08mg IV and was extubated. She became fully conscious with good respiratory efforts postoperatively, with heart rate at 134 beats/min and SpO_2 at 100%. She was shifted to NICU for observation for 24hrs, remained stable and was shifted to the ward after 24 hrs to be discharged after 15 days.

DISCUSSION

After the development of valve regulated shunts in 1950's, many surgeries have been widely used to treat hydrocephalus. High failure rates and numerous complications have been reported with the introduction of neuroendoscopic procedures.[5] Endoscopic third ventriculostomy has become the preferred treatment for obstructive hydrocephalus because it is minimally invasive and offers the surgeon with a brilliant visual control of the manoevure.[6]

In the anaesthetic management of our case, we anticipated difficult intubation due to proportionately very large size of her head; hence, we prepared ourselves for difficult airway management. An interrupted ventilation would have lead to hypoxia and/or hypercarbia with associated raised intracranial pressure (ICP). We arranged additional equipment including facemasks, oropharyngeal airways, tracheal tubes, laryngeal mask airways of different sizes, a set of bougies and laryngoscope blades of different types appropriate for our patient. Pediatric fiberoptic bronchoscope was not available with us at that time. Weight appropriate breathing circuit was checked for correct configuration and patency. Standard monitoring like pulse oximetry, electrocardiogram, non invasive blood pressure, capnography and nasal temperature measurement were instituted.

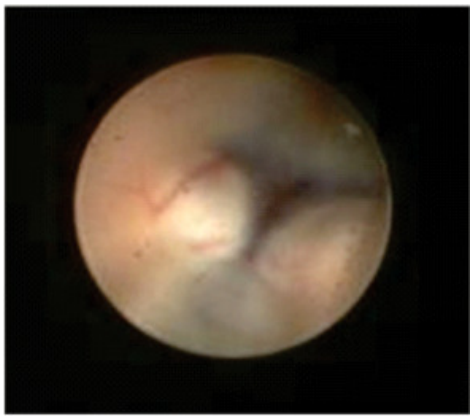

Fig 3: Endoscopic view of floor of third ventricle.

For proper alignment of oral, pharyngeal and laryngeal axis to facilitate intubation, we used an adequate size shoulder pad and small rolled towels on both sides for the patient. Additionally, an assistant was asked to raise the upper chest by his hand as and when needed. Sedative premedication may mask the signs of neurological dysfunction; conversely an anxious patient can have detrimental rise in ICP during induction.[7] Hence, we

used sedation very cautiously in appropriate doses and monitored carefully throughout the surgery.

Volume status and normothermia were also adequately managed intraoperatively in our case. Baby remained stable throughout perioperative period. After the procedure, she had adequate respiratory efforts with stable vital signs, hence reversal and extubation was considered without elective postoperative ventilatory support. Baby was monitored in the NICU post operatively for a day and was shifted to the ward and later discharged.

Fig 4: Endoscopic view after the third ventriculostomy

Intraoperative haemodynamic changes during ETV have been extensively studied with conflicting results. Murshid reported increased intracranial pressure could cause tachycardia and systemic hypertension due to high speed fluid irrigation or kinking of the outflow tube.[8] Cushing response can occur due to compression of hypothalamus by dilated third ventricle.[8] Bayken et al[9] reported intraoperative bradycardia in 28.1% and the respective rates for asystole and bradycardia were 0.5% and 12.4% with overall incidence of arrhythmia as 41%. Increasing ICP indefinitely would lead to cardiac arrest. Leach *et al* [10] reported in two occasions during ETV a profound bradycardia leading to short lived, spontaneously resolving episodes of asystole.

Intraoperatively, during fenestration, vascular injuries like rupture of basilar artery can occur leading to haemorrhage. Bayken et al[9] reported five cases of mild venous bleeding which was controlled by irrigation. Early complications include transient ocular divergence, anisocoria and hyponatremia. Five children were diagnosed with temporary diabetes insipidus in late postoperative period. High pressure levels inside the endoscope during the procedure can occur without haemodynamic warning signs. Any pressure >30 mm Hg are associated with post operative morbidity especially unexpected delay in recovery and neurological deficits.[11] The use of dexamethasome is widely exercised to reduce ICP, although its use for this purpose has been questioned.

Another issue of interest following ETV is postoperative electrolyte imbalance like hyperkalemia, probably due to hormonal dysfunction and the use of lactated ringer solution for irrigation.[6,12] Anandh et al reported a significant bradycardia at the time of fenestration and at the time of reversal of the neuromuscular block.[13] The procedure was also associated with a postoperative hyperkalemia. They proposed a mechanism involving distortion of the posterior hypothalamus, which accounts for the bradycardia and postoperative hyperkalemia.

Hence a well-planned perioperative management of anaesthesia is required for a neurosurgical procedure like ETV to reduce the perioperative morbidity and mortality. Though, the neuroendoscopic approach is considered safe for treating hydrocephalus in children, complications can be severe and lethal and the anaesthesiologist must respond accordingly.

CONCLUSION

ETV is effective in treating obstructive hydrocephalus and is effective in two-thirds of the patients with previous infections. With the increasing use of this technique now days, understanding the pathophysiological changes that occur could be important. We conclude that a well planned peri-operative management by the anesthesiologist can contribute to a better recovery and outcome for this technique.

REFERENCES

1. El-Dawlatly AA, Murshid WR, Elshimy A, Magboul MA, Samarkandi A, Takrouri MS. The incidence of bradycardia during endoscopic third ventriculostomy. Anesth Analg 2000;91:1142-4.
2. El-Dawlatly A, Elgamal E, Murshid W, Alwatidy S, Jamjoom Z, Alshaer A. Anesthesia for third ventriculostomy: A report of 128 cases. Middle East J Anesthesiol 2008 ;19:847-57.
3. Jones RF, Stening WA, Brydon M. Endoscopic third ventriculostomy. Neurosurgery 1990;26:86-

92.

4. Ambesh SP, Kumar R. Neuroendoscopic procedures: Anesthetic considerations for a growing trend: a review. J Neurosurg Anesthesiol 2000;12:262-70.

5. Fàbregas N, López A, Valero R, Carrero E, Caral L, Ferrer E. Anesthetic management of surgical neuroendoscopies: Usefulness of monitoring the pressure inside the neuroendoscope. J Neurosurg Anesthesiol 2000;12:21-8.

6. Rezaee O, Sharifi G, Samadian M, Haddadian K, Ali-Asgari A, Yazdani M. Endoscopic third ventriculostomy for treatment of obstructive hydrocephalus. Arch Iran Med 2007;10:498-503.

7. Sunderland R, Mallory S. Anaesthesia for ventriculo-peritoneal shunt insertion. Anesthesia tutorial of the week 121. World Federation of Societies of Anaesthesiologists Internet. 2008 Dec cited 2008 Dec 8;121. Available from: http://totw.anaesthesiologists.org/2008/12/08/ananaesthesia-for-ventriculo-peritoneal-shunt-insertion-121/

8. Murshid WR. Endoscopic third ventriculostomy: Towards more indications for the treatment of non-communicating hydrocephalus. Minim Invasive Neurosurg 2000;43:75-82.

9. Baykan N, Isbir O, Gerçek A, Dağçnar A, Ozek MM. Ten years of experience with paediatric neuroendoscopic third ventriculostomy: Features and perioperative complications of 210 cases. J Neurosurg Anesthesiol 2005;17:33-7.

10. Leach P, Thorne J, Palmer J. Response to: Ten years experience with paediatric neuroendoscopic ventriculostomy features and perioperative complications of 210 cases. J Neurosurg Anesthesiol 2005;17:172.

11. Hopf NJ, Grunert P, Fries G, Resch KD, Perneczky A. Endoscopic third ventriculostomy: Outcome analysis of 100 consecutive procedures. Neurosurgery 1999;44:795-804.

12. Derbent A, Erşahin Y, Yurtseven T, Turhan T. Hemodynamic and electrolyte changes in patients undergoing neuroendoscopic procedures. Childs Nerv Syst 2006;22:253-7.

13. Anandh B, Madhusudan Reddy KR, Mohanty A, Umamaheswara Rao GS, Chandramouli BA. Intraoperative bradycardia and post operative hyperkalemia in patients undergoing endoscopic third ventriculostomy. Minim Invasive Neurosurg 2002;45:154-7.